

Is There a Special Role for Ovarian Hormones in the Pathogenesis of Lobular Carcinoma?

Renée L. Flaherty,¹ George Sflomos,² and Cathrin Briskin^{1,2} 

¹Division of Breast Cancer Research, The Breast Cancer Now Toby Robins Research Centre, The Institute of Cancer Research, London SW3 6JB, UK

²Swiss Institute for Experimental Cancer Research, School of Life Sciences, Ecole Polytechnique Fédérale de Lausanne (EPFL), CH-1015 Lausanne, Switzerland

Correspondence: Cathrin Briskin, MD, PhD, ISREC, School of Life Sciences, Ecole Polytechnique Fédérale Lausanne (EPFL), SV2.832 Station 19, CH-1015 Lausanne, Switzerland. Email: Cathrin.briskin@epfl.ch, cathrin.briskin@icr.ac.uk; or Renée L. Flaherty, PhD, Division of Breast Cancer Research, The Breast Cancer Now Toby Robins Research Centre, The Institute of Cancer Research, 237 Fulham Road, London SW3 6JB, UK. Email: renee.flaherty@icr.ac.uk.

Abstract

Lobular carcinoma represent the most common special histological subtype of breast cancer, with the majority classed as hormone receptor positive. Rates of invasive lobular carcinoma in postmenopausal women have been seen to increase globally, while other hormone receptor-positive breast cancers proportionally have not followed the same trend. This has been linked to exposure to exogenous ovarian hormones such as hormone replacement therapy. Reproductive factors resulting in increased lifetime exposure to endogenous ovarian hormones have also been linked to an increased risk of lobular breast cancer, and taken together, these data make a case for the role of ovarian hormones in the genesis and progression of the disease. In this review, we summarize current understanding of the epidemiological associations between ovarian hormones and lobular breast cancer and highlight mechanistic links that may underpin the etiology and biology.

Key Words: invasive lobular carcinoma, estrogen receptor, progesterone receptor, hormone replacement therapy, hormonal contraception, androgenic progestins

Abbreviations: DCIS, ductal carcinoma in situ; ER+, estrogen receptor positive; HRT, hormone replacement therapy; IC-NST, invasive carcinoma of no special type; IDC, invasive ductal carcinoma; ILC, invasive lobular carcinoma; LCIS, lobular carcinoma in situ; PR, progesterone receptor; RR, relative risk.

The majority of breast cancers (70–80%) are hormone receptor positive (1–3), and ovarian hormone receptor signaling is critical for the progression of the disease (4, 5). Over the past 3 decades epidemiological data have implicated exposure to exogenous sources of hormones, such as those from oral contraceptives and hormone replacement therapy (HRT), with an increased risk of estrogen receptor-positive (ER+) breast cancer (6–8). This suggests a role for ovarian hormones in the etiology of breast cancer, as well as driving its progression. However, there have been observations that this risk is not equal for all ER+ breast cancers (9).

Lobular Breast Cancer Characteristics and Incidence

Most ER+ breast cancers have been classified histologically as invasive ductal carcinoma (IDC), and recently reclassified by the World Health Organization as invasive carcinoma of no special type (IC-NST or NST). This was to remove confusion on the histogenic origin and highlight the lack of any specific differentiating features used to distinguish the other special subtypes of breast cancer (10). Of the special histological subtypes of breast cancer, lobular carcinoma is the most common, accounting for 10% to 15% of all cases. Lobular carcinoma in situ (LCIS) and primary invasive lobular carcinoma (ILC) are most often classified as luminal A by molecular subtyping and

express both ER and progesterone receptor (PR) and are KI67 low and HER2 negative. Rarely triple negative lobular cases occur, accounting for 1% to 1.5% of all triple negative breast cancers (11–13).

Lobular carcinomas are primarily characterized by the distinctive single file infiltration of small, atypical tumor cells into the surrounding stroma. The loss of E-cadherin, seen in ~90% of ILC cases, is thought to underpin this characteristic growth pattern (14, 15). On the molecular level, ILCs show specific gene loss and mutational landscapes compared with non-ILCs, including enrichment for mutations in tumor suppressors and transcriptional regulators of ER (16, 17). Mammography is notoriously less sensitive for ILC detection than for non-ILC due to the diffuse growth patterns; consequently, ILCs are more often diagnosed at a later stage (11, 18). Distinct patterns of metastatic spread characterize ILCs, with metastases frequently seen in the ovaries, gastrointestinal tract, and leptomeninges (19), and decreased rates of metastasis to the liver and lungs compared with ER+ NST (20). Clinically, ILC has a good prognosis and treatment is informed by hormone receptor status, with the vast majority responding to endocrine therapy (21). However, a subset of patients with ILC have been shown to respond less favorably to certain endocrine therapies, implying intrinsic resistance (21, 22). While survival rates are comparable between ILC

and ER-positive NST initially, some studies have shown long-term outcomes for ILC are worse (23, 24).

Given the increasing appreciation that ILC differs from other HR-positive breast cancers, exposure to exogenous sources of hormones such as oral contraceptives and HRTs may therefore have specific implications in the genesis and progression of the disease.

Evidence of this can be seen in the epidemiological data from the United States that show a rise in the rate of lobular breast cancer up until the early 2000s (1.52-fold), whereas rates for NST have remained stable (1.03-fold) (25-29). During this period, the prescription of HRT also increased; however, at the turn of the century, following results from landmark studies linking HRT to an increased risk of breast cancer, there was a substantial drop in its use (30, 31). This was mirrored by an 11.6% decrease in all cases of invasive breast cancer between 1999 and 2004, but the steepest decline was seen in ILC (-4.6%) compared with -3.3% for IDC (29, 30). Several factors, such as changing diagnostic practices and detection of early lesions, could conceivably contribute to this decrease in invasive carcinomas; however, a growing body of evidence points to a stronger link between exposure to exogenous hormones in the form of HRT, and an increased risk of lobular carcinoma compared with nonlobular (8).

This review aims to explore the role of ovarian hormones in the context of lobular breast cancer, with particular focus on the risk associated with exposure to exogenous hormone sources. A comprehensive literature search of the PubMed database was conducted using the keywords “invasive lobular carcinoma,” “hormone replacement therapy,” “hormonal contraception,” and “reproductive risk factors.”

Ovarian Hormones as a Risk Factor for Lobular Breast Cancer

The ovarian hormones estrogen and progesterone orchestrate postnatal growth and development of the breast, and as such have been consistently implicated in breast carcinogenesis (32-34). All cancers of the breast arise in the terminal ductal lobular units (35), which lie located at the ends of the branching ducts in the breast. Like the subtending milk ducts, terminal ductal lobular units are lined with luminal epithelial cells, a proportion of which express ovarian hormone receptors, signaling through which stimulates changes in the breast (36). Reproductive factors, including early onset of menarche, shorter menstrual cycles, nulliparity, and late menopause, increase exposure of the breast to endogenous hormones over the course of a lifetime and are associated with increased risk of breast cancer. Conversely, pregnancy before the age of 30 and breast feeding, which reduce cumulative exposure, are considered protective factors (32, 34) whereas pregnancies after 30 are not and actually increase risk (37).

Although the cumulative exposure to ovarian hormones has been implicated in the etiology of breast cancer, it remains difficult to assess the data regarding specific histological subtypes due to differences in the use of the terminology, changes in terminology, and different histopathological interpretations. Discordance between pathologists has been reported, with the inclusion of staining for E-cadherin improving the agreement between pathologists on ILC vs non-ILC calls (38). As referenced previously, the classification of breast cancers has been updated to clarify that invasive carcinomas with no other special features are termed NST. Many epidemiological

studies in relation to ILC use IDC terminology, when in actuality they are referring to a group of HR-positive NST.

Reproductive Factors

The Million Women study showed that early onset of menarche was associated with relative risk (RR) of 1.22 for lobular vs 1.02 for ER+ NST (referred to as ductal) in women with an age at menarche <12. The trend for decreasing risk with increasing age at menarche was observed to be most pronounced for lobular carcinomas, while little difference was observed in ductal and other special subtypes (39). This association was corroborated in a meta-analysis of epidemiological studies linking breast cancer and reproductive risk factors. RR of lobular carcinoma was significantly increased compared with ductal with every year younger at menarche and every year older at menopause (32).

Other studies have validated that the interval between menarche and age at first birth is a risk factor for lobular carcinomas (40). Data from the Nurses' Health Study in the United States show that later age at first birth is associated with increased risk for both histological subtypes, but risk is higher for ILC than IDC (RR 1.63 vs 1.1) for an age at first birth between 25 and 29, and rising to (RR 2.31 vs 1.21) the 30-34 age bracket (41). Further epidemiological evidence also highlights age at first birth as risk factor for lobular carcinoma specifically (39, 42-44). Interestingly, whereas nulliparity was associated with increased risk for lobular over ductal (42), the protective effects of parity observed with other subtypes of breast cancer was not observed for lobular carcinomas (45).

The patterns of risk associated with reproductive factors and lobular breast cancer indicate that hormone exposures may differentially impact individual histologic subtypes of breast cancer. These differences cannot wholly be explained by the differential expression of hormone receptors between ILC and NST (46, 47), and persists even after restriction to ER+ PR+ or luminal A tumors (41, 48).

Oral Contraceptives

Hormonal contraceptives comprise synthetic PR agonists—progestins, either on their own (minipill) or combined with estrogens, mostly the more readily absorbable ethinyl estradiol (49). Multiple meta-analyses and large epidemiological studies have confirmed that the use of oral contraceptives is associated with a modest increase in the RR of breast cancer in women, but subsides after cessation of use (6, 49-51). However, other studies have found little or no association between oral contraceptive use of any kind and specific molecular subtypes or hormone receptor status (52-55).

Oral contraceptive use is more strongly associated with ER+ breast cancer in young women, particularly high-dose estrogenic formulations (56). With regards to histologic variations, in a cohort of over 6000 women adjusted for other reproductive factors current oral contraceptive use was associated with increased risk of lobular but not ductal carcinomas (odds ratio [OR] 2.6 vs 1.2), and decreased with time since last use. However, data on the specific type of contraceptive were not included and the population were on average middle-aged (57). Interestingly, this association for current use was not seen in an age-adjusted case-control study into reproductive risk factors. However former oral contraceptive use was associated with increased risk of lobular compared with ductal cancer (OR 1.43 vs 0.96) (48). In contrast, in a study of

premenopausal women no difference in RR of lobular or ductal carcinoma and ever use oral contraceptive was seen (58). Yet, in women over 65 years of age, use for over 5 years conferred a greater increase in risk of lobular relative to ductal breast cancer (59), suggesting that the risk of oral contraceptives may differ by age.

Risk has also been shown to be greater for certain formulations of oral contraceptives containing synthetic progestins (60, 61). In a UK case-control study, use of progestin-only oral contraceptives and intrauterine devices had a modest but significant effect on breast cancer risk (OR 1.26 and OR 1.3), although the risk did not differ substantially between ER-negative/positive tumors (62). We have recently shown that androgenic progestins such as levonorgestrel, which are structurally similar to testosterone, promote cell proliferation in xenografted human breast epithelia whereas antiandrogenic progestins do not (63). While the clinical relevance of preclinical studies needs to be carefully considered, a study from Finland where information from the pharmacy records and the cancer registry can be linked supports this notion. Exposure to levonorgestrel, released from contraceptive IUDs, despite resulting in low systemic levels of this androgenic progestin, increased the risk of breast cancer, and did so in particular for lobular subtype (OR 1.33 vs 1.2) (64).

The histological subtype of breast cancer may therefore be influenced by hormones present in contraceptives, although the many studies simply stratify use by previous, current or never, which fails to account for different routes of administration, dose, and regimens, all of which may differentially affect breast cancer risk.

Hormone Replacement Therapy

HRT is used to relieve the symptoms of menopause resulting from cessation of ovarian function and can comprise estrogen-only or combined estrogen and progestin (65).

Some early studies regarding HRT and breast cancer noted that the strongest risk was associated with invasive breast cancers with favorable prognoses (66-68). In 2000, a US study found that women who had used combined estrogen and progestin-containing HRT vs never users had a greater RR of developing lobular carcinoma over ductal (69). Continuous use of progestin-containing therapy for 3 or more years increased the risk of ILC significantly (70, 71). Combined HRT use (up to 15 years) increased RR for all subtypes but most substantially for lobular, whereas extended use of estrogen-only HRT did not.

However, as is often the case in epidemiological studies involving ILC, the lower numbers of ILCs mean these studies are under powered (72). A case-control study specifically designed to interrogate the association between HRT and histological subtype that recruited equal numbers of both histological subtypes and found current use of both formulations of HRT were significantly associated with an increased risk of ILC (73). However, significance was only reached with 9 or more years of use for estrogen-only HRT whereas 3 years of combined HRT was sufficient to increase ILC risk.

Data gathered in the Nurses' Health study in the United States as well as 2 well-powered Scandinavian studies also found that combined HRT had the greatest effect on lobular breast cancer risk (41, 74, 75). These findings were reiterated

by The Million Women study, one of the only observational studies of the requisite power to assess the RR of HRT (7, 9). Compared with never use, current use of HRT was associated with higher risk for lobular over ductal carcinoma (RR 2.25 vs 1.63). Similarly, the use of combination therapy conferred a greater risk for lobular vs ductal (RR 2.80 vs 2.00) and use for 10 or more years widened this gap (RR 3.52 vs 2.52)

These studies add weight to the conclusion that exposure to estrogens alone does not account for the increase in the risk of lobular cancer in women using HRT, and the addition of progestins has a more adverse impact on lobular breast cancer risk specifically. In support of this, the use of combined HRT was shown to be associated with increased risk of ER+/PR+, but not ER+/PR- or ER-/PR- breast cancers (72). The conclusion is further corroborated by a meta-analysis of data collected from postmenopausal women that brings together the vast majority of current literature on HRT (8). Analysis shows that current estrogen-only HRT use increased the risk of lobular vs ductal carcinomas (RR 1.58 vs 1.25), but that this difference was much greater for combined HRT (RR 2.72 vs 1.89). Furthermore, when stratified by receptor expression, the risk posed by use of estrogen-only HRT for +10 years was only slightly higher for ER+ vs ER- tumors (RR 1.61 vs 1.43), whereas for combined HRT it was substantially greater for ER+ cases than ER- (RR 2.7 vs 1.43). The addition of progestin therefore seems to have the most significant effect on RR.

Considering the role of progestins, a case-control study looking at risk by histological subtype found variability in RR across combined HRT dosing regimens and formulations (76). Higher risk was seen across subtypes for testosterone-derived progestins than for continuously administered bioidentical progesterone-derived progestins. Although the authors concede this may be an artefact of dosing regimen as opposed to potency. In France, a similar observation was made, with no increase in risk posed by natural progestogenic components of combined HRT, whereas synthetic progestins increased the risk of lobular cancer more strongly compared to ductal (77). It was also noted that androgenic testosterone-derived progestogens increased risk to the greatest extent for breast cancer overall.

There are several factors to consider when interpreting the studies summarized in Table 1. While it may be intuitive to compare lobular carcinomas with NST, there is a case to call into question the usefulness of this comparison. Considering the clinical management of ILC does not differ to that of other breast cancers with the same hormone receptor status, and both fall under the category of luminal A and some B, it may be worth making comparisons between cancers clustered by their molecular subtypes instead. Indeed, some studies have taken this approach and observed current or ever use of HRT makes no contribution to the risk of developing luminal A breast cancer above other subtypes (81, 82), while others have reported that HRT use was specifically associated with only luminal A cancers (80, 83).

Nonetheless, the studies summarized in Table 1 comparing (13 001) lobular vs (19 038) nonlobular breast cancers represent a not insignificant body of evidence demonstrating that HRT use is associated with increased risk of lobular breast cancer over nonlobular ER+ breast cancers. Moreover, stimulation of the ER, PR, and potentially the

Table 1. Summary of studies

Study	Cohort (n)	Findings
O'Connor et al, 1998 (68)	10 lobular, 41 ductal	The incidence of lobular BC was significantly higher in a cohort of women taking HRT than in nonusers
Gapstur et al, 1999 (66)	101 invasive lobular, 1164 total	There was no association with ever use of HRT and invasive ductal, lobular or DCIS. HRT was not separated by estrogen or progestin containing
Schairer et al, 2000 (67)	104 lobular, 788 ductal	Use of EHRT and CHRT were both associated with significant increased risk in a ductal/lobular combined cohort, as well as ductal alone. Lobular alone was not assessed
Li et al, 2000 (69)	58 lobular, 370 ductal	Using CHRT elevated the risk of lobular breast cancer but not ductal. EHRT use only slightly increased risk for lobular.
Daling et al, 2002 (70)	263 lobular, 1386 ductal	EHRT was not associated with lobular or ductal BC risk, CHRT was associated with an increased risk of lobular over ductal. Sequential use of progestin-containing (CHRT) was associated with lower risk of lobular than continuous use
Beral et al, 2003 (7)	7140 invasive breast cancer	Risk of breast cancer (not separated by histologic subtype) was associated with current use of HRT, and risk was higher with current use of CHRT than EHRT
Li et al, 2003 (78)	196 lobular, 656 ductal, 114 "other"	EHRT was not associated with increased risk of BC. Use of CHRT either current or ever was associated with an increased risk of invasive BC, with the greatest risk for invasive lobular BC. Long-term use was associated with the greatest risk
Lyytinen et al, 2006 (79)	53 lobular, 271 ductal	Use of oral or transdermal estradiol formulations for 5 years or more increased the risk of lobular slightly over ductal
Rosenberg et al, 2006 (74)	308 lobular, 1888 ductal	Exclusive use of EHRT was significantly associated with increased risk of lobular, and, to a lesser extent, ductal carcinomas. Risk associated with >5 years of CHRT were higher for lobular BC, as was continuous use vs sequential. There were significant trends with duration of use.
Reeves et al, 2006 (9)	1526 invasive lobular, 8007 ductal, 365 mixed	Current use of both EHRT and CHRT was associated with increased risk of invasive lobular and mixed lobular-ductal over ductal; however, the risk was higher for CHRT
Phipps et al, 2008 (80)	1023 luminal	CHRT associated with an increased risk of luminal breast cancer over HER2+ and TN disease
Flesch-Janys et al, 2008 (76)	670 invasive lobular, 2229 ductal, 153 mixed.	Ever use and current use, but not past use, were associated with an increased risk of invasive lobular and mixed lobular-ductal cancer. CHRT was associated with the highest risk compared with EHRT, as was continuous use compared with sequential.
Li et al, 2008 (40)	324 lobular, 196 mixed ductal-lobular, 524 ductal	Current CHRT use increased risk of lobular and mixed ductal-lobular breast cancer incidence significantly over ductal. EHRT was associated with a decreased risk for ductal but not lobular or mixed cases
Chlebowski et al, 2010 (81)	56 lobular, 676 in total	CHRT was associated with an increased in invasive breast cancer. There was no difference in effect between ER+ and ER- tumors
Islam et al, 2012 (82)	554 luminal (A + B)	Low levels of HRT use in cohort, no association seen across subtypes
Cordina-Duverger et al, 2013 (77)	125 lobular, 586 ductal	n < 15 for HRT use in lobular cases. CHRT with synthetic progestagens was more strongly associated with increased risk of ER+ BC overall, and lobular over ductal carcinoma
Li et al, 2014 (73)	1027 lobular, 880 ductal	In postmenopausal women short term or form use was not associated with risk of lobular or ductal. Current long-term CHT (and to a lesser extent EHT) use was significantly associated with increased risk of lobular BC
Suhrke et al, 2015 (75)	539 invasive lobular, 4058 nonlobular	Use of CHRT for over a year was associated with increased risk of invasive lobular BC, and to a lesser extent invasive nonlobular BC
Ellingjord-Dale et al, 2017 (83)	2985 luminal A	CHRT was associated with increased risk of luminal A breast cancer, but not HER+ or TN.
Mullooly et al, 2017 (84)	86 LCIS, 1448 DCIS	Current use of was more strongly associated with an increased risk of LCIS compared with DCIS. HRT was not separated by formulation
Timbres et al, 2023 (85)	338 LCIS, 3075 DCIS	Long-term use of HRT was associated with a greater risk of LCIS over DCIS. No difference in risk with formulation was observed

Abbreviations: BC, breast cancer; CHRT, combined estrogen and progestin hormone replacement therapy; DCIS, ductal carcinoma in situ; ER, estrogen receptor; EHRT, estrogen-only hormone replacement therapy; HRT, hormone replacement therapy.

androgen receptor by use of combined HRT containing androgenic progestins has the greatest effect on risk of ILC. In at least 2 studies, observations were made that compared with ductal carcinoma in situ (DCIS) HRT was associated with an increased risk of LCIS—an obligate precursor of ILC (7, 85). This suggests that while stimulation of ovarian hormone receptors by HRT may promote the progression of ILC to a greater extent, the development of early lobular disease is also preferentially stimulated by HRT.

Mechanistic Links Between Ovarian Hormones and Lobular Carcinoma

Hormone Receptor Biology

Differences in hormone receptor biology may provide mechanistic insights into why ovarian hormones exert the greatest effect on ILC development and progression.

In vitro stimulation of ILC cells with 17 β -estradiol increased the half-life of the ER, whereas in IDC cell line

stimulation of the ER had the opposite effect, inducing degradation (86). Stimulation of the ER also induced a unique gene expression signature not observed in non-ILC lines (87). These ILC-specific differences in ER signaling were further probed in patient datasets, whereby gene expression and protein levels were less concordant in ILC samples vs IDC, indicating a potential role for post-translational modification of ER in ILC (86). Selective ER downregulation was less effective in reducing 17 β -estradiol-induced proliferation in vitro in ILC compared with IDC cells. Indeed, selective ER downregulation elicited partial agonistic activity in ILC cell lines, potentially through a unique recruitment of ER coregulators (86). However, because of the limited number of models available, it is not clear whether differences are truly subtype specific or related to interpatient heterogeneity.

The differential regulation of the ER in lobular carcinoma was further underlined through the identification of MDC1 as an ILC-specific ER coregulator in ILC cell lines. MDC1 was not only required for ER-stimulated proliferation, but an essential mediator of the ER transcriptome and was rarely lost in lobular tumors vs IDC (88). Molecular profiling of patients with ILC and IDC also revealed several other distinct patterns of genomic alterations (17, 89). Mutations in *GATA3*, a transcription factor that induces luminal differentiation and controls ER expression, were observed less frequently in ILC than IDC, suggesting that ILC cells may rely on different mechanisms regulating ER signaling (17). Conversely, mutations in *FOXA1*, a key transcriptional regulator of ER activity that opens condensed chromatin to allow ER to bind at specific sites, promoting ER-induced cell proliferation, are more frequent in ILC than IDC. Furthermore, ILC cell lines and tumors possess a distinct chromatin state enriched for *FOXA1* binding (90), preserving ER binding and providing a mechanism for the increased frequency of tamoxifen resistance observed clinically in ILCs (22). A critical mediator of mammary gland development, *WNT4*, has also been proposed as a driver of endocrine resistance in ILC. *WNT4* was significantly upregulated in response to estrogen specifically in ILC lines (87), and was shown to be directly under the control of ER as is the mouse mammary epithelium (91). *WNT4* signaling was also necessary for estrogen-induced proliferation, and in models of endocrine therapy-resistant ILC was crucial to maintain cell growth (92).

In LCIS, E-cadherin loss is already observed in the majority of cases (93), and while there is some evidence to suggest a role for the ER in the suppression of E-cadherin (94, 95), it is not considered the primary mechanism and does not explain why hormonal exposure may drive ILC progression over ER+ NST. LCIS is also highly ER+ (~90-100%—summarized in (96)), whereas only ~70% of DCIS cases are classified as ER+ (97). The average age of women diagnosed with LCIS is reportedly also younger at ~50 (98, 99) compared with 57 for DCIS (100). Given these differences, it is tempting to propose a mechanism by which younger women who have developed undiagnosed LCIS go on to start HRT, which promotes progression to invasive lobular disease. ILCs are also often diagnosed at a later stage, so the length of exposure to HRT may be longer.

In a study of premenopausal women, the annual hazard rate peaks for women with HR+ IDC after 5 years and then subsides, whereas risk of recurrence remains elevated for ILC over 10+ years. The overall differences in hazard rates are small and no information was given regarding HRT use, but

this suggests lobular disease that develops in the premenopausal setting is more likely to be hormone sensitive. As such any additional stimulation by HRT upon commencement of the menopause could further exacerbate already elevated risk (101).

Examination of the role of the PR, an ER target gene (102), may also provide insight regarding the development of lobular disease. Phosphorylation of the progesterone receptor expressed on mammary stem cells is hypothesized to be a key event in neoplastic luminal progression of ER+/PR+ breast cancers (103). Moreover, phospho-PR and PR target genes were significantly upregulated in ILC—indicating a potential mechanism by which PR stimulation in the mammary stem cell compartment may contribute to the development of ILC. Progesterone is also known to induce mammary stem cell population expansion (104) and proliferation in the non-malignant human breast driven by paracrine mechanisms (105, 106).

In xenograft models of ILC, both progesterone alone and to a greater extent in combination with estradiol stimulated the growth of tumor cells (107). While classic PR antagonists have not been as efficacious as hoped, due in part to toxicity/reported adverse events (108, 109), given the apparent role of PR signaling, new-generation selective PR modulators may provide useful alternatives in ILC, especially given the frequent resistance to selective ER modulators.

Effects of Hormone Signaling in the Breast Stroma

In postmenopausal women with high body mass index (BMI), the majority of estrogen synthesis occurs in the adipose tissue. This can mask the effects of HRT on breast cancer risk (ie, the exogenous hormones have little effect in addition to the elevated endogenous production) (110). However, data suggest that the risk of ILC is elevated for HRT users independent of BMI, as the correlation between increasing BMI and decreasing risk was observed only in ductal carcinomas (111). Furthermore, although high BMI was not seen to be an independent prognostic indicator in ILC, obesity was associated with a higher tumor grade (112).

Alongside effects on epithelial and tumor cells, hormone stimulation also affects the surrounding stroma. Breast density as measured by mammography identifies fibroglandular tissue within the breast, comprising epithelial cells, stromal cells, and connective tissue. In analysis from the Women's Health Initiative, estrogen plus progestin increased mammographic density and subsequent breast cancer risk in postmenopausal women (113, 114), findings corroborated by others (115).

Fibrillar collagen density correlates with mammographic density (116, 117), and has also been shown to be regulated by hormonal changes during reproductive cycles (118). This may have particular implications for lobular disease as ILCs are enriched for extracellular matrix interactions, and tumor cells from ILC patient-derived xenografts display higher expression of matrix components such as collagens and elastin at transcript level (119). This evidence demonstrates that ILC cells contribute to the deposition of matrix, but may also preferentially grow in a collagen dense environment. A hypothesis supported by the finding that risk of progression from LCIS to invasive disease increased with breast density (120).

Therefore, increased breast density driven by hormonal exposure and characterized by increased collagen density may

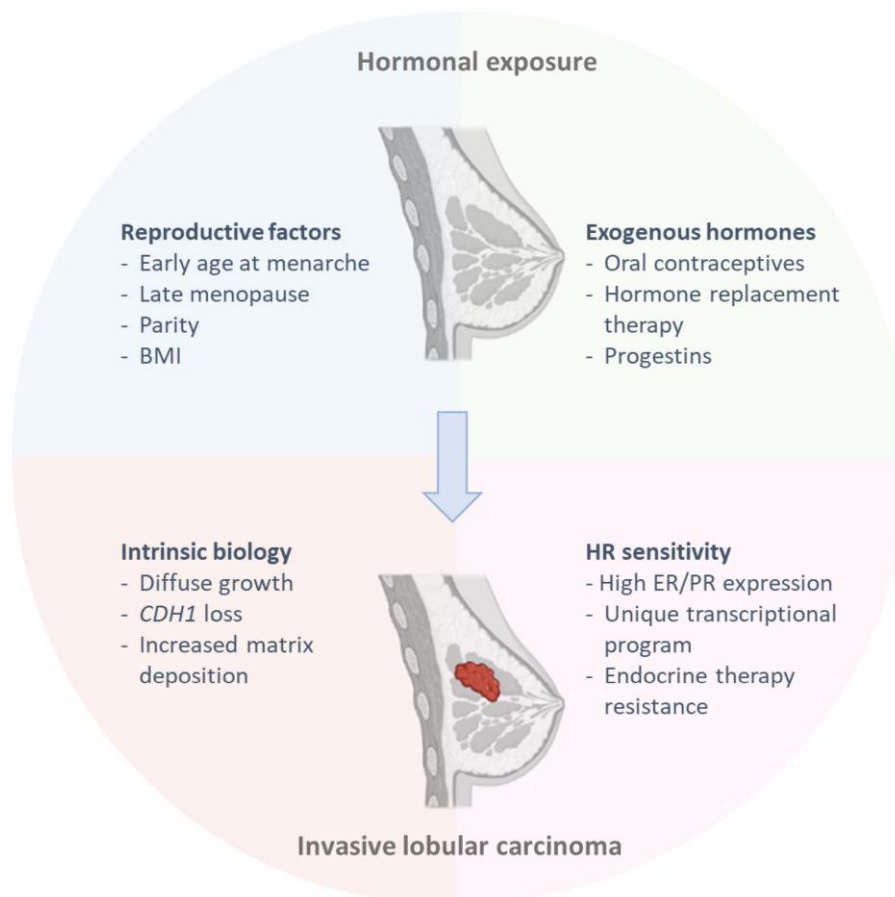


Figure 1. Factors associated with ILC genesis and progression. Reproductive factors that increase exposure of the breast to ovarian hormones, and exogenous hormones sources—in particular estrogen and progestin-containing HRT—are associated with an increased risk of invasive lobular carcinoma (ILC). Once established the characteristic features of ILC and unique hormone receptor biology may drive progression, underpinning the differential response to hormone stimulation and ultimately endocrine therapy. Figure created with Biorender.

support the development of ILC, feasibly providing a link between HRT/oral contraceptives and increased risk of ILC.

Conclusions

The epidemiological evidence is increasingly strong for a causal link between ovarian hormones and lobular breast cancer, particularly relating to HRT use. The risk associated with HRT is higher than that associated with oral contraceptives, indicating that exposure to exogenous hormones has the most pronounced effect on risk in older women, suggesting tumor-promoting effects. Mechanistically, differences in hormone receptor biology may underpin specific events driven by ovarian hormones that lead to the genesis of lobular carcinoma preferentially over other HR-positive breast cancers. It can also be hypothesized that a feedback loop exists, whereby lobular carcinomas respond differentially to hormone receptor stimulation and stromal signals, and in turn regulate hormone receptor signaling differentially, ultimately affecting response to hormone therapies (Fig. 1).

What is most obvious, however, is that lobular biology is distinct from that of other HR+ breast cancers, and a case can be made that this needs to be considered in clinical management. Several clinical trials are now underway to explore ILC-specific treatments that exploit its unique features, and preclinically the development of representative ILC models

will allow a better understanding of the effects of hormones on the progression of ILC (121).

Since HRT remains an essential tool for improving the quality of life for women, it should be noted that type and timing of use are important factors to take into consideration, with the majority of studies indicating that cessation of use returns risk to baseline after 5 years (9). Raising awareness of the risks associated with exogenous hormones, and in particular increased screening in HRT users with a focus on the detection of lobular disease should also be considered.

Funding

C.B. has support from Breast Cancer Now and H2020-MSCA-ITN (ITN-2019-859860-CANCERPREV). This work was supported by Breast Cancer Now as part of program funding to the Breast Cancer Now Toby Robins Research Centre (to C.B.).

Disclosures

C. Briskin is a member of the editorial board for Endocrinology. The authors have no conflicts of interest.

Data Availability

Data sharing is not applicable to this article as no datasets were generated or analyzed during the current study.

References

1. Perou CM, Sørlie T, Eisen MB, *et al.* Molecular portraits of human breast tumours. *Nature*. 2000;406(6797):747-752.
2. Tavassoli FA. *Pathology and Genetics of Tumours of the Breast and Female Genital Organs*. World Health Organization Classification of Tumours; 2003.
3. Weigelt B, Horlings HM, Kreike B, *et al.* Refinement of breast cancer classification by molecular characterization of histological special types. *J Pathol*. 2008;216(2):141-150.
4. Pike MC, Spicer DV, Dahmouch L, *et al.* Estrogens, progestogens, normal breast cell proliferation, and breast cancer risk. *Epidemiol Rev*. 1993;15(1):17-35.
5. Capper CP, Rae JM, Auchus RJ. The metabolism, analysis, and targeting of steroid hormones in breast and prostate cancer. *Horm Cancer*. 2016;7(3):149-164.
6. Collaborative Group on Hormonal Factors in Breast, C. Breast cancer and hormonal contraceptives: collaborative reanalysis of individual data on 53 297 women with breast cancer and 100 239 women without breast cancer from 54 epidemiological studies. *Lancet (London, England)*. 1996;347(9017):1713-1727.
7. Beral V. Breast cancer and hormone-replacement therapy in the Million Women Study. *Lancet*. 2003;362(9392):419-427.
8. Cancer CGOHBIB. Type and timing of menopausal hormone therapy and breast cancer risk: individual participant meta-analysis of the worldwide epidemiological evidence. *Lancet*. 2019;394(10204):1159-1168.
9. Reeves GK, Beral V, Green J, *et al.* Hormonal therapy for menopause and breast-cancer risk by histological type: a cohort study and meta-analysis. *Lancet Oncol*. 2006;7(11):910-918.
10. Sinn H-P, Kreipe H. A brief overview of the WHO classification of breast tumors, 4th edition, focusing on issues and updates from the 3rd edition. *Breast care*. 2013;8(2):149-154.
11. Luveta J, Parks RM, Heery DM, *et al.* Invasive lobular breast cancer as a distinct disease: implications for therapeutic strategy. *Oncol Ther*. 2020;8(1):1-11.
12. Bergeron A, MacGrogan G, Bertaut A, *et al.* Triple-negative breast lobular carcinoma: a luminal androgen receptor carcinoma with specific ESRRA mutations. *Mod Pathol*. 2021;34(7):1282-1296.
13. Conforti F, Pala L, Pagan E, *et al.* Biological and clinical features of triple negative Invasive Lobular Carcinomas of the breast. Clinical outcome and actionable molecular alterations. *Breast*. 2021;59:94-101.
14. McCart Reed AE, Kutasovic JR, Lakhani SR, *et al.* Invasive lobular carcinoma of the breast: morphology, biomarkers and 'omics. *Breast Cancer Res*. 2015;17(1):12-12.
15. Morrogh M, Andrade VP, Giri D, *et al.* Cadherin-catenin complex dissociation in lobular neoplasia of the breast. *Breast Cancer Res Treat*. 2012;132(2):641-652.
16. Korhonen T, Huhtala H, Hollli K. A comparison of the biological and clinical features of invasive lobular and ductal carcinomas of the breast. *Breast Cancer Res Treat*. 2004;85(1):23-29.
17. Ciriello G, Gatz M, Beck A, *et al.* Comprehensive molecular portraits of invasive lobular breast cancer. *Cell*. 2015;163(2):506-519.
18. Van Baelen K, Geukens T, Maetens M, *et al.* Current and future diagnostic and treatment strategies for patients with invasive lobular breast cancer. *Ann Oncol*. 2022;33(8):769-785.
19. Mollica L, Leli C, Puglisi S, *et al.* Leptomeningeal carcinomatosis and breast cancer: a systematic review of current evidence on diagnosis, treatment and prognosis. *Drugs Context*. 2021;10:2021-6-6.
20. Mathew A, Rajagopal P, Villgran V, *et al.* Distinct pattern of metastases in patients with invasive lobular carcinoma of the breast. *Geburtshilfe Frauenheilkd*. 2017;77(06):660-666.
21. Rakha EA, El-Sayed ME, Powe DG, *et al.* Invasive lobular carcinoma of the breast: response to hormonal therapy and outcomes. *Eur J Cancer*. 2008;44(1):73-83.
22. Metzger Filho O, Giobbie-Hurder A, Mallon E, *et al.* Relative effectiveness of letrozole compared with tamoxifen for patients with lobular carcinoma in the BIG 1-98 trial. *J Clin Oncol*. 2015;33(25):2772-2779.
23. Adachi Y, Ishiguro J, Kotani H, *et al.* Comparison of clinical outcomes between luminal invasive ductal carcinoma and luminal invasive lobular carcinoma. *BMC Cancer*. 2016;16(1):248.
24. Pestalozzi BC, Zahrieh D, Mallon E, *et al.* Distinct clinical and prognostic features of infiltrating lobular carcinoma of the breast: combined results of 15 International Breast Cancer Study Group clinical trials. *J Clin Oncol*. 2008;26(18):3006-3014.
25. Verkooijen HM, Fioretta G, Vlastos G, *et al.* Important increase of invasive lobular breast cancer incidence in Geneva, Switzerland. *Int J Cancer*. 2003;104(6):778-781.
26. Verkooijen HM, Koot VCM, Fioretta G, *et al.* Hormone replacement therapy, mammography screening and changing age-specific incidence rates of breast cancer: an ecological study comparing two European populations. *Breast Cancer Res Treat*. 2008;107(3):389-395.
27. Li CI, Anderson BO, Porter P, *et al.* Changing incidence rate of invasive lobular breast carcinoma among older women. *Cancer*. 2000;88(11):2561-2569.
28. Li CI, Daling JR, Malone KE. Age-Specific incidence rates of in situ breast carcinomas by histologic type, 1980 to 2001. *Cancer Epidemiol Biomarkers Prev*. 2005;14(4):1008.
29. Ehemann CR, Shaw KM, Ryerson AB, *et al.* The changing incidence of in situ and invasive ductal and lobular breast carcinomas: united States, 1999-2004. *Cancer Epidemiol Biomarkers Prev*. 2009;18(6):1763-1769.
30. Writing Group for the Women's Health Initiative, I. Risks and benefits of estrogen plus progestin in healthy postmenopausal WomenPrincipal results from the Women's health initiative randomized controlled trial. *JAMA*. 2002;288(3):321-333.
31. Wysowski DK, Governale LA. Use of menopausal hormones in the United States, 1992 through June, 2003. *Pharmacoepidemiol Drug Saf*. 2005;14(3):171-176.
32. Collaborative Group on Hormonal Factors in Breast, C. Menarche, menopause, and breast cancer risk: individual participant meta-analysis, including 118 964 women with breast cancer from 117 epidemiological studies. *Lancet Oncology*. 2012;13(11):1141-1151.
33. Travis RC, Key TJ. Oestrogen exposure and breast cancer risk. *Breast Cancer Res*. 2003;5(5):239-247.
34. Key TJ, Verkasalo PK, Banks E. Epidemiology of breast cancer. *Lancet Oncol*. 2001;2(3):133-140.
35. Wellings SR, Jensen HM. On the origin and progression of ductal carcinoma in the human breast2. *JNCI: J Natl Cancer Inst*. 1973;50(5):1111-1118.
36. Brisken C, O'Malley B. Hormone action in the mammary gland. *Cold Spring Harb Perspect Biol*. 2010;2(12):a003178.
37. Ewertz M, Duffy SW, Adami H, *et al.* Age at first birth, parity and risk of breast cancer: a meta-analysis of 8 studies from the Nordic countries. *Int J Cancer*. 1990;46(4):597-603.
38. Christgen M, Kandt LD, Antonopoulos W, *et al.* Inter-observer agreement for the histological diagnosis of invasive lobular breast carcinoma. *J Pathol Clin Res*. 2022;8(2):191-205.
39. Reeves GK, Pirie K, Green J, *et al.* Reproductive factors and specific histological types of breast cancer: prospective study and meta-analysis. *Br J Cancer*. 2009;100(3):538-544.
40. Li CI, Malone KE, Daling JR, *et al.* Timing of menarche and first full-term birth in relation to breast cancer risk. *Am J Epidemiol*. 2008;167(2):230-239.
41. Kotsopoulos J, Chen WY, Gates MA, *et al.* Risk factors for ductal and lobular breast cancer: results from the nurses' health study. *Breast Cancer Res*. 2010;12(6):R106-R106.
42. Newcomb PA, Trentham-Dietz A, Hampton JM, *et al.* Late age at first full term birth is strongly associated with lobular breast cancer. *Cancer*. 2011;117(9):1946-1956.

43. Li CI, Littman AJ, White E. Relationship between age maximum height is attained, age at menarche, and age at first full-term birth and breast cancer risk. *Cancer Epidemiol Biomarkers Prev.* 2007;16(10):2144-2149.
44. Butt S, Borgquist S, Anagnostaki L, et al. Parity and age at first childbirth in relation to the risk of different breast cancer subgroups. *Int J Cancer.* 2009;125(8):1926-1934.
45. Ursin G, Bernstein L, Lord SJ, et al. Reproductive factors and subtypes of breast cancer defined by hormone receptor and histology. *Br J Cancer.* 2005;93(3):364-371.
46. Arpino G, Bardou VJ, Clark GM, Elledge RM. Infiltrating lobular carcinoma of the breast: tumor characteristics and clinical outcome. *Breast Cancer Res.* 2004;6(3):R149-R156.
47. Metzger O, Cardoso F, Poncet C, et al. 6 oral—clinical utility of MammaPrint testing in invasive lobular carcinoma: results from the MINDACT phase III trial. *Eur J Cancer.* 2020;138:S5-S6.
48. Williams LA, Nichols HB, Hoadley KA, et al. Reproductive risk factor associations with lobular and ductal carcinoma in the Carolina breast cancer study. *Cancer Causes & Control: CCC.* 2018;29(1):25-32.
49. Gierisch JM, Coeytaux RR, Urrutia RP, et al. Oral contraceptive use and risk of breast, cervical, colorectal, and endometrial cancers: a systematic review. *Cancer Epidemiol Biomarkers Prev.* 2013;22(11):1931.
50. Breast cancer and hormonal contraceptives: further results. Collaborative group on hormonal factors in breast cancer. *Contraception.* 1996;54(3 Suppl):1s-106s.
51. Romieu I, Willett WC, Colditz GA, et al. Prospective study of oral contraceptive use and risk of breast cancer in women. *J Natl Cancer Inst.* 1989;81(17):1313-1321.
52. Turkoz FP, Solak M, Petekkaya I, et al. Association between common risk factors and molecular subtypes in breast cancer patients. *Breast.* 2013;22(3):344-350.
53. Ma H, Wang Y, Sullivan-Halley J, et al. Use of four biomarkers to evaluate the risk of breast cancer subtypes in the women's contraceptive and reproductive experiences study. *Cancer Res.* 2010;70(2):575-587.
54. Althuis MD, Brogan DD, Coates RJ, et al. Breast cancers among very young premenopausal women (United States). *Cancer Causes Control.* 2003;14(2):151-160.
55. Gaudet MM, Press MF, Haile RW, et al. Risk factors by molecular subtypes of breast cancer across a population-based study of women 56 years or younger. *Breast Cancer Res Treat.* 2011;130(2):587-597.
56. Beaver EF, Buist DSM, Barlow WE, et al. Recent oral contraceptive use by formulation and breast cancer risk among women 20 to 49 years of age. *Cancer Res.* 2014;74(15):4078-4089.
57. Newcomer LM, Newcomb PA, Trentham-Dietz A, et al. Oral contraceptive use and risk of breast cancer by histologic type. *Int J Cancer.* 2003;106(6):961-964.
58. Nyante SJ, Gammon MD, Malone KE, et al. The association between oral contraceptive use and lobular and ductal breast cancer in young women. *Int J Cancer.* 2008;122(4):936-941.
59. Li CI, Malone KE, Porter PL, et al. Reproductive and anthropometric factors in relation to the risk of lobular and ductal breast carcinoma among women 65–79 years of age. *International Journal of Cancer.* 2003;107(4):647-651.
60. Hunter DJ, Colditz GA, Hankinson SE, et al. Oral contraceptive use and breast cancer: a prospective study of young women. *Cancer Epidemiol Biomarkers Prev.* 2010;19(10):2496-2502.
61. Conz L, Mota BS, Bahamondes L, et al. Levonorgestrel-releasing intrauterine system and breast cancer risk: a systematic review and meta-analysis. *Acta Obstet Gynecol Scand.* 2020;99(8):970-982.
62. Fitzpatrick D, Pirie K, Reeves G, et al. Combined and progestagen-only hormonal contraceptives and breast cancer risk: a UK nested case-control study and meta-analysis. *PLoS Med.* 2023;20(3):e1004188.
63. Shamseddin M, De Martino F, Constantin C, et al. Contraceptive progestins with androgenic properties stimulate breast epithelial cell proliferation. *EMBO Mol Med.* 2021;13(7):e14314.
64. Soini T, Hurskainen R, Grénman S, et al. Levonorgestrel-releasing intrauterine system and the risk of breast cancer: a nationwide cohort study. *Acta Oncol.* 2016;55(2):188-192.
65. Beral V, Bull D, Reeves G. Endometrial cancer and hormone-replacement therapy in the million women study. *Lancet.* 2005;365(9470):1543-1551.
66. Gapstur SM, Morrow M, Sellers TA. Hormone replacement therapy and risk of breast cancer with a favorable HistologyResults of the Iowa Women's health study. *JAMA.* 1999;281(22):2091-2097.
67. Schairer C, et al. Menopausal estrogen and estrogen-progestin replacement therapy and breast cancer risk. *Jama.* 2000;283(4):485-491.
68. O'Connor IF, Shembekar MV, Shousha S. Breast carcinoma developing in patients on hormone replacement therapy: a histological and immunohistological study. *J Clin Pathol.* 1998;51(12):935.
69. Li CI, Weiss NS, Stanford JL, Daling JR. Hormone replacement therapy in relation to risk of lobular and ductal breast carcinoma in middle-aged women. *Cancer.* 2000;88(11):2570-2577.
70. Daling JR, Malone KE, Doody DR, et al. Relation of regimens of combined hormone replacement therapy to lobular, ductal, and other histologic types of breast carcinoma. *Cancer.* 2002;95(12):2455-2464.
71. Li CI, Malone KE, Porter PL, et al. Relationship between menopausal hormone therapy and risk of ductal, lobular, and ductal-lobular breast carcinomas. *Cancer Epidemiol Biomarkers Prev.* 2008;17(1):43-50.
72. Li CI, et al. Relationship between long durations and different regimens of hormone therapy and risk of breast cancer. *Jama.* 2003;289(24):3254-3263.
73. Li CI, Daling JR, Haugen KL, et al. Use of menopausal hormone therapy and risk of ductal and lobular breast cancer among women 55–74 years of age. *Breast Cancer Res Treat.* 2014;145(2):481-489.
74. Rosenberg LU, Magnusson C, Lindström E, et al. Menopausal hormone therapy and other breast cancer risk factors in relation to the risk of different histological subtypes of breast cancer: a case-control study. *Breast Cancer Res.* 2006;8(1):R11-R11.
75. Suhrke P, Zahl P-H. Breast cancer incidence and menopausal hormone therapy in Norway from 2004 to 2009: a register-based cohort study. *Cancer Med.* 2015;4(8):1303-1308.
76. Flesch-Janys D, Slinger T, Mutschelknauss E, et al. Risk of different histological types of postmenopausal breast cancer by type and regimen of menopausal hormone therapy. *Int J Cancer.* 2008;123(4):933-941.
77. Cordina-Duverger E, Truong T, Anger A, et al. Risk of breast cancer by type of menopausal hormone therapy: a case-control study among post-menopausal women in France. *PLoS One.* 2013;8(11):e78016.
78. Li CI, Anderson BO, Daling JR, et al. Trends in incidence rates of invasive lobular and ductal breast carcinoma. *JAMA.* 2003;289(11):1421-1424.
79. Lyytinen H, Pukkala E, Ylikorkala O. Breast cancer risk in postmenopausal women using estrogen-only therapy. *Obstet Gynecol.* 2006;108(6):1354-1360.
80. Phipps AI, Malone KE, Porter PL, et al. Reproductive and hormonal risk factors for postmenopausal luminal, HER-2–overexpressing, and triple-negative breast cancer. *Cancer.* 2008;113(7):1521-1526.
81. Chlebowski RT, Anderson GL, Gass M, et al. Estrogen plus progestin and breast cancer incidence and mortality in postmenopausal women. *JAMA.* 2010;304(15):1684-1692.
82. Islam T, Matsuo K, Ito H, et al. Reproductive and hormonal risk factors for luminal, HER2–overexpressing, and triple-negative breast cancer in Japanese women. *Ann Oncol.* 2012;23(9):2435-2441.

83. Ellingjord-Dale M, Vos L, Tretli S, *et al.* Parity, hormones and breast cancer subtypes—results from a large nested case-control study in a national screening program. *Breast Cancer Res.* 2017;19(1):10.
84. Mullooly M, Khodr ZG, Dallal CM, *et al.* Epidemiologic risk factors for in situ and invasive breast cancers among postmenopausal women in the national institutes of health-AARP diet and health study. *Am J Epidemiol.* 2017;186(12):1329-1340.
85. Timbres J, Kohut K, Caneppele M, *et al.* DCIS and LCIS: are the risk factors for developing in situ breast cancer different? *Cancers (Basel).* 2023;15(17):4397.
86. Sreekumar S, Levine KM, Sikora MJ, *et al.* Differential regulation and targeting of estrogen receptor α turnover in invasive lobular breast carcinoma. *Endocrinology.* 2020;161(9):bqaa109.
87. Sikora MJ, Cooper KL, Bahreini A, *et al.* Invasive lobular carcinoma cell lines are characterized by unique estrogen-mediated gene expression patterns and altered tamoxifen response. *Cancer Res.* 2014;74(5):1463.
88. Sottnik JL, Bordeaux EK, Mehrotra S, *et al.* Mediator of DNA damage checkpoint 1 (MDC1) is a novel estrogen receptor coregulator in invasive lobular carcinoma of the breast. *Mol Cancer Res.* 2021;19(8):1270-1282.
89. Desmedt C, Zoppoli G, Sotiriou C, *et al.* Transcriptomic and genomic features of invasive lobular breast cancer. *Semin Cancer Biol.* 2017;44:98-105.
90. Nardone A, Qiu X, Spisak S, *et al.* A distinct chromatin state drives therapeutic resistance in invasive lobular breast cancer. *Cancer Res.* 2022;82(20):3673-3686.
91. Rajaram RD, Buric D, Caikovski M, *et al.* Progesterone and wnt4 control mammary stem cells via myoepithelial crosstalk. *EMBO J.* 2015;34(5):641-652.
92. Sikora MJ, Jacobsen BM, Levine K, *et al.* WNT4 mediates estrogen receptor signaling and endocrine resistance in invasive lobular carcinoma cell lines. *Breast Cancer Res.* 2016;18(1):92-92.
93. Vos C, Cleton-Jansen AM, Berx G, *et al.* E-cadherin inactivation in lobular carcinoma in situ of the breast: an early event in tumorigenesis. *Br J Cancer.* 1997;76(9):1131-1133.
94. Oesterreich S, Deng W, Jiang S, *et al.* Estrogen-mediated down-regulation of E-cadherin in breast cancer cells. *Cancer Res.* 2003;63(17):5203-5208.
95. Cardamone MD, Bardella C, Gutierrez A, *et al.* ER α as ligand-independent activator of CDH-1 regulates determination and maintenance of epithelial morphology in breast cancer cells. *Proc Natl Acad Sci USA.* 2009;106(18):7420.
96. Logan GJ, Dabbs DJ, Lucas PC, *et al.* Molecular drivers of lobular carcinoma in situ. *Breast Cancer Research: BCR.* 2015;17(1):76-76.
97. Miligy IM, Toss MS, Shiino S, *et al.* The clinical significance of oestrogen receptor expression in breast ductal carcinoma in situ. *Br J Cancer.* 2020;123(10):1513-1520.
98. King TA, Pilewskie M, Muhsen S, *et al.* Lobular carcinoma in situ: a 29-year longitudinal experience evaluating clinicopathologic features and breast cancer risk. *J Clin Oncol.* 2015;33(33):3945-3952.
99. van Maaren MC, Ávila AO, van Manen JG, *et al.* Trends in incidence, treatment, survival and subsequent breast cancer in lobular carcinoma in situ in The Netherlands: a population-based analysis. *Breast.* 2021;59:376-382.
100. Giannakeas V, Sopik V, Narod SA. Association of a diagnosis of ductal carcinoma in situ with death from breast cancer. *JAMA Netw Open.* 2020;3(9):e2017124-e2017124.
101. Yoon TL, Jeong J, Lee S, *et al.* Survival outcomes in premenopausal patients with invasive lobular carcinoma. *JAMA Netw Open.* 2023;6(11):e2342270-e2342270.
102. Hilton HN, Graham JD, Clarke CL. Minireview: progesterone regulation of proliferation in the normal human breast and in breast cancer: a tale of two scenarios? *Mol Endocrinol.* 2015;29(9):1230-1242.
103. Knutson TP, Truong TH, Ma S, *et al.* Posttranslationally modified progesterone receptors direct ligand-specific expression of breast cancer stem cell-associated gene programs. *J Hematol Oncol.* 2017;10(1):89-89.
104. Asselin-Labat ML, Vaillant F, Sheridan JM, *et al.* Control of mammary stem cell function by steroid hormone signalling. *Nature.* 2010;465(7299):798-802.
105. Beleut M, Rajaram RD, Caikovski M, *et al.* Two distinct mechanisms underlie progesterone-induced proliferation in the mammary gland. *Proc Natl Acad Sci U S A.* 2010;107(7):2989-2994.
106. Tanos T, Sfllomos G, Echeverria PC, *et al.* Progesterone/RANKL is a Major regulatory axis in the human breast. *Sci Transl Med.* 2013;5(182):182ra55.
107. Scabia V, Ayyanan A, De Martino F, *et al.* Estrogen receptor positive breast cancers have patient specific hormone sensitivities and rely on progesterone receptor. *Nat Commun.* 2022;13(1):3127.
108. Claudia L, Wargon V, Rojas P, *et al.* Antiprogestins in breast cancer treatment: are we ready? *Endocr Relat Cancer.* 2012;19(3):R35-R50.
109. Jonat W, Bachelot T, Ruhstaller T, *et al.* Randomized phase II study of lonaprisan as second-line therapy for progesterone receptor-positive breast cancer. *Ann Oncol.* 2013;24(10):2543-2548.
110. Morimoto LM, White E, Chen Z, *et al.* Obesity, body size, and risk of postmenopausal breast cancer: the Women's health initiative (United States). *Cancer Causes Control.* 2002;13(8):741-751.
111. Li CI, Malone KE, Daling JR. Interactions between body mass index and hormone therapy and postmenopausal breast cancer risk (United States). *Cancer Causes Control.* 2006;17(5):695-703.
112. Van Baelen K, Nguyen H-L, Hamy-Petit A-S, *et al.* Association of body mass index with clinicopathological features and survival in patients with primary invasive lobular breast cancer. *Eur J Cancer.* 2023;191:112988.
113. Byrne C, Ursin G, Martin CF, *et al.* Mammographic density change with estrogen and progestin therapy and breast cancer risk. *J Natl Cancer Inst.* 2017;109(9):dxx001.
114. Chlebowski RT, Hendrix SL, Langer RD, *et al.* Influence of estrogen plus progestin on breast cancer and mammography in healthy postmenopausal women: the Women's health Initiative Randomized Trial. *Jama.* 2003;289(24):3243-3253.
115. Kerlikowske K, Cook AJ, Buist DSM, *et al.* Breast cancer risk by breast density, menopause, and postmenopausal hormone therapy use. *J Clin Oncol.* 2010;28(24):3830-3837.
116. Bodelon C, Mullooly M, Pfeiffer RM, *et al.* Mammary collagen architecture and its association with mammographic density and lesion severity among women undergoing image-guided breast biopsy. *Breast Cancer Res.* 2021;23(1):105.
117. Huo CW, Chew G, Hill P, *et al.* High mammographic density is associated with an increase in stromal collagen and immune cells within the mammary epithelium. *Breast Cancer Res.* 2015;17(1):79.
118. Guo Q, Sun D, Barrett AS, *et al.* Mammary collagen is under reproductive control with implications for breast cancer. *Matrix Biol.* 2022;105:104-126.
119. Sfllomos G, Battista L, Aouad P, *et al.* Intraductal xenografts show lobular carcinoma cells rely on their own extracellular matrix and LOXL1. *EMBO Mol Med.* 2021;13(3):e13180.
120. Minami CA, Zabor EC, Gilbert E, *et al.* Do body mass Index and breast density impact cancer risk among women with lobular carcinoma in situ? *Ann Surg Oncol.* 2020;27(6):1844-1851.
121. Sfllomos G, Schipper K, Koorman T, *et al.* Atlas of lobular breast cancer models: challenges and strategic directions. *Cancers (Basel).* 2021;13(21):5396.